JOURNAL OF CONSERVATIVE DENTISTRY

Home
Current issue
Instructions
Submit article

J Conserv Dent. 2017 Nov-Dec; 20(6): 386–391. PMCID: PMC5799982
doi: 10.4103/JCD.JCD_157_16

Incremental techniques in direct composite restoration

Veeramachaneni Chandrasekhar, Laharika Rudrapati, Vijetha Badami, and Muralidhar Tummala

Department of Conservative Dentistry and Endodontics, Mamata Dental College, Khammam, Telangana, India
Address for correspondence: Dr. Laharika Rudrapati, Department of Conservative Dentistry and Endodontics, Mamata Dental College, Giriprasad Nagar, Khammam, Telangana, India. E-mail: paula.june24@gmail.com

Received 2016 Apr 19; Revised 2016 Oct 20; Accepted 2017 Nov 29.

Abstract

Go to:

Polymerization shrinkage is one of the dental clinician's main entanglements when placing resin-based composite restorations. None of the method can assure a perfectly sealed restoration for adhesive restorative materials; clinicians must abode problems of polymerization shrinkage and its possible ill effects. The objective of this article is to review different incremental techniques that can ruin the polymerization shrinkage stress of direct composite restoration.

Keywords: Composites, incremental techniques, layering techniques, polymerization shrinkage

INTRODUCTION

Go to:

Composite resins today occupy a paramount position among restorative materials for they offer exemplary esthetic potential and acceptable longevity, with a much lower cost than equivalent ceramic restorations for the treatment of both anterior and posterior teeth.[1,2,3,4] In addition, composite restorations allow for minimally invasive or no preparation at all when assuming the replacement of decayed or missing tissues which gives thinking to a new concept called Bio Esthetics. It is in the limelight that all composite resins shrink during polymerization leading to adhesive and cohesive failure. This shrinkage presents several challenges during placement and photocuring.[5,6,7,8,9,10]

Factors affecting polymerization shrinkage include C-factor, filler content, degree of conversion, elastic modulus, water sorption,light-curing variables, and influence of substrate.

Restoration placement techniques are universally recognized as a considerable factor in the modification of shrinkage stress. By maneuvering specific restorative techniques, stress resulting from constrained shrinkage may be scaled down. Per contra, it is not clear which restorative technique should be used to demolish shrinkage stress. Administering the composite in layers instead of using a bulk technique is recommended to reduce shrinkage stress.[10]

Three main factors concur to reduce shrinkage stress: use of a small volume of material, a lower cavity configuration factor, and minimal contact with the opposing cavity walls during polymerization. It is widely accepted that incremental filling decreases shrinkage stress as a result of reduced polymerization material volume. Each increment is compensated by the next, and the consequence of polymerization shrinkage is less damaging since only the volume reduction of the last layer can damage the bond surface.[11]

INCREMENTAL TECHNIQUES FOR DIRECT COMPOSITE RESTORATION

Go to:

When placing posterior composites, the use of small increments is recommended by many authors for insertion and polymerization so that the after effect of shrinkage stress can be reduced.

Considering anterior composite restorations, though the placement of successive increments aids to knockdown the effects of polymerization shrinkage stress, errors in layering techniques result in restorations which are too translucent or opaque. So to ensure esthetically pleasing results, layering concepts should be lucid, standardized, and reproducible.

Incremental techniques

Horizontal layering technique The horizontal placement technique utilizes composite resin layers, each <2.0 mm thick [Figure 1]. This technique has been reported to increase the C-factor, and thereupon increases the shrinkage stresses between the opposing cavity walls.[12,13,14]

Figure 1
Horizontal layering technique

Oblique layering technique The oblique technique is accomplished by placing a series of wedge-shaped composite increments. Each increment is photocured twice, first through the cavity walls and then from the occlusal surface, to direct the vectors of polymerization toward the adhesive surface [Figure 2]. This technique reduces the C-factor and prevents the distortion of cavity walls.[11,12,13,14]

Figure 2
Oblique layering technique

Vertical layering technique Place small increments in vertical pattern starting from one wall, i.e., buccal or lingual and carried to another wall. Start polymerization from behind the wall, i.e., if buccal increment is placed on the lingual wall, it is cured from outside of the lingual wall. This reduces gap at gingival wall which is formed due to polymerization shrinkage, hence postoperative sensitivity and secondary caries [Figure 3].

Figure 3
Vertical layering technique

Stratified layering technique The stratified layering technique was schemed and oriented to the development of functional and anatomic restoration applying the “esthetic” composite resin restorative materials that include shades of dentin and enamel as well as various translucencies and intensive colors.[15,16,17] This technique is designed to engrave various degrees of chroma present within a tooth. It involves placing dentin shades of composite resin with a higher chroma in the middle of the preparation and placing a lower chroma resin close to the cusp walls. The stratified layering technique is accomplished by placing initial dentin layers of composite shades or chromas that are two or three degrees higher than the selected basic shade or chroma. Subtle variations in dentin color can be achieved by changing the thickness of each chroma layer in specific areas of the restoration. The enamel layer is placed following the contours established by the dentin layers and it varies in thickness depending on the desired effect. The enamel layer can be remodeled by placing various shades of opalescent or intensive enamels on distinct areas of the restoration. Further effects can be produced using resin-intensive colors or stains.[15,16]

Centripetal buildup technique

The centripetal buildup technique offers a number of advantages when composite resin posterior restorations are indicated. This technique employs thin metal matrix bands and wooden wedges eliminating the need for transparent matrix bands, which may not provide firm contact areas and anatomical proximal contours [Figure 4] and are cumbersome to use for many practitioners. Further, recent studies do not indicate any detriment of metal matrix bands in cervical gap formation.[18]

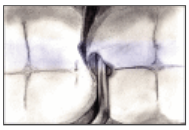

Figure 4
Centripetal buildup technique (showing proximal composite semitransparent layer placed toward the matrix band using composite)

An important benefit of the procedure is offered by the centripetal buildup steps first by creating a very thin proximal layer [Figure 4]; the internal curing [Figure 5] of this layer is affected which can strengthen the composite and cut down cervical gap that could form.[19,20] Furthermore, even if such gap does develop, the next consecutive layer which is condensed toward the gingival floor is likely to fill gap since the continuity of space created is not occluded. Comparative microleakage tests have yet to be conducted but the author's experience of more than 6 years with this technique has demonstrated excellent marginal adaptation radiographically. The formation of occlusal surface ring is another significant addition of the proposed technique. By building a continuous layer to cusp slopes, an occlusal reference surface is created, avoiding overfilling and minimizing the subsequent need for rotary burs. These finishing procedures are known to be detrimental to outer surface of composite.[21] Finally, the centripetal buildup technique is very conservative with preservation of sound tooth structure; it is not time-consuming and it is easy to implement. Once the second step of the procedure is completed and peripheral composite envelope is created, the cavity is managed as a simple Class I cavity. The systemic use of enamel and dentin shades achieves predictable and pleasing esthetic results Figure 6. The centripetal buildup technique has been exercised profitably where small to medium posterior restoration is indicated. However, when directly restoring extensive stress-bearing occlusal surfaces, especially in molars, silver amalgam when manipulated meticulously is still the material of choice to achieve a long-lasting dental restoration.

Figure 5
A schematic drawing illustrating use of intracavity extension tip

Figure 6
Completed restoration demonstrating various layers of centripetal buildup technique

Split-increment horizontal layering technique When the conventional horizontal technique is utilized, each composite increment that connects the cavity floor with the four surrounding walls produces the highest and the most unfavorable C-factor ratio of 5 when it is photocured.[12,13,14] Concern has been expressed about placing individual increments against opposing walls simultaneously before photocuring, as the resulting polymerization shrinkage stress may cause the cusps to bend toward each other and deform as a result This stress may cause postoperative sensitivity and can be detrimental to the tooth and the marginal integrity over time.[22] For the proposed technique, each horizontal increment was split, before curing, into four triangle-shaped portions [Figure 7], with each portion placed against only one cavity wall and part of the floor one diagonal cut was filled completely with dentin shade composite and photocured. At this point, the other diagonal cut was filled and photocured, one half at a time. The same technique is followed until dentin-enamel junction and later enamel shade composite followed by translucent shade are placed and shaped to establish occlusal morphology. This sequence would prevent composite resin from connecting two opposing cavity walls simultaneously, minimizing the negative effects of polymerization shrinkage on

the cavity walls and adhesive interfaces. This would even reduce the C-factor ratio from 5, which is the highest and the most unfavorable, to the second most favorable C-factor ratio of 0.5.

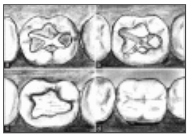

Figure 7
Split incremental technique (a) the two diagonal cuts split first uncured horizontal increment of dentin shade into four triangle-shaped portions, this followed by photocuring from buccal lingual and occlusal directions (b and c) complete filling of one ...

Such small increment portions with a low C-factor ratio would relieve the shrinkage stress by the free composite surface flowing at the diagonal cuts and not at the bonded interfaces, minimizing the adverse effects of polymerization shrinkage stresses.[23]

Successive cusp buildup technique Here, individual cusps are restored one at a time up to the level of the occlusal enamel. Small sloping increments are applied to each corner of the cavity [Figure 8] in turn and manipulation is kept to a minimum, to avoid folding voids into the material. This method, while initially time-consuming, can greatly reduce finishing time by precise attention to progressive reconstruction of natural morphology.[24]

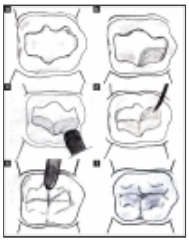

Figure 8
(a) Adhesive applied on prepared cavity (b) mesiolingual incremental placed (c) distolingual incremental placed (d) mesiobuccal incremental placed (e) centrobuccal incremental placed (f) distobuccal incremental placed showing completed restoration

Separate dentine and enamel buildup Here, sloping increments are again applied to cavity walls [Figure 9] (and cured in turn) but only to the level of the amelodentinal junction. Final "enamel" increments are then applied. Prudent control of the final layer will again reduce the finishing stage. Some operators (if agreeable to the patient) place composite pit and fissure stain before placement of the final layer. An alternative method of achieving a more natural appearance is to use a dark (e.g., A4) shade of composite for the bulk of the restoration and a translucent or light shade for the "enamel" increment.[25,26]

Figure 9
(a) Buccal dentin restored (b) lingual dentin restored (c) final enamel layer restored showing finished restoration

Separate dentine and enamel buildup - using an index This variation can be used when restoring a carious tooth with an intact occlusal surface. After dam placement, a preoperative impression is taken of the occlusal. Once layered "dentine" restoration is complete, the impression material is used to aid precise adaptation of the final "enamel" increment(s). With careful control of the amount of composite used, this technique may completely exclude the finishing stage [Figure 10].[24]

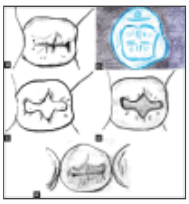

Figure 10
Separate dentin and enamel buildup using an index (a) Preoperative view of Class I Dental Caries (DC) (b) preoperative impression of occlusal surface (using silicon putty) (c) cavity preparation completed (d) incremental restoration using dentin shade ...

Three-site technique This is a layering technique that is associated with the use of a clear matrix and reflective wedges. First, the curing light is directed through the matrix and wedges in the attempt to guide the polymerization vectors toward the gingival margin thus preventing any gap formation. Then,

wedge-shaped composite increments are placed to further inhibit distortion of cavity walls and reduce the C-factor [Figure 11]. This technique is associated with polymerization first through the cavity walls and then from the occlusal surface in order to direct the vectors of polymerization toward the adhesive surface.[11]

Figure 11
Three-site technique

Bulk technique The bulk technique is recommended by some authors to reduce stress at the cavosurface margins.[11]

While anterior composite restorations are ubiquitous, breakthrough multiple layering techniques using a range of shades, opacities, and translucencies remains the domain of relatively few practitioners. The following basic dual-shade and more complicated multilayered (polychromatic) placement sequences are presented as methodical guidelines for all clinicians longing to create more natural-looking direct anterior composite restorations.

Dual-shade layering technique

Basic practitioners are recommended to establish confidence in layering techniques by beginning with two material shades as this simplified technique is reported to deliver an acceptable color match in a large number of clinical situations. Following etching and adhesive application, an opaque dentine material is applied, shaped, and light cured. Most dentine restorative materials are in the shade group A and selection of the correct chroma is a key to success. Palatal, proximal, and labial enamel increments are then layered, freehand over the opacious central core at approximately half the thickness of residual enamel.[27]

Polychromatic layering technique

When esthetic demands are high, the widely accepted stratification technique proposed by Lorenzo Vanini is recommended.[28] The fundamental principle of polychromatic layering technique is to use different composite shades to replicate the layers seen in natural teeth which can be described in layers as palatal enamel layer, dentine layer, special features, opalescents, characterizations, and intensives.[29]

Comparative review According to Nadig *et al*., incremental technique showed lower microleakage compared to bulk. Among the incremental techniques, split horizontal incremental technique showed least microleakage followed by centripetal technique and oblique placement technique at occlusal margin of Class II restoration. At the gingival margin, there was no significant difference in microleakage between centripetal incremental and oblique placement technique, and split horizontal incremental technique showed least microleakage.[30]

In a study done by Khier and Hassan where the efficacy of three placement techniques in marginal sealing of Class V composite restorations extending onto the root has been compared, they concluded that oblique and occlusogingival incremental techniques exhibited higher degrees of microleakage at occlusal and gingival margins, as compared to that of split-increment technique. Splitting flat composite increment by diagonal cut, before light curing, preserved bonded gingival margin integrity and reduced microleakage.[31]

According to Susanne Szep *et al*. who evaluated the effect of two different proximal restoration techniques (centripetal versus incremental) with different matrix systems (metal and transparent matrices) on marginal seal and microhardness of Class II composite restorations, they concluded that lowest, however, not significantly different microleakage was achieved in totally bonded deep Class II restorations prepared with margins surrounded by enamel when using transparent matrices sand reflective wedges in combination with centripetal buildup technique. Highest surface hardness of composite resin was related to transparent matrices and reflecting wedges.[32]

CONCLUSION

Go to:

Direct composite restorations have become a pivotal part of the active dental practice. Methods to upgrade efficiency and speed of their placement should be incorporated with the objective of long-lasting and properly formed restorations. A meticulous operative technique along with appropriate case selection governs the success of resin composite restoration.

Financial support and sponsorship

Nil.

Conflicts of interest

There are no conflicts of interest.

REFERENCES

Go to:

1. Osborne JW, Norman RD, Gale EN. A 12-year clinical evaluation of two composite resins. Quintessence Int. 1990;21:111–4. [PubMed]

2. Hickel R, Manhart J. Longevity of restorations in posterior teeth and reasons for failure. J Adhes Dent. 2001;3:45–64. [PubMed]

3. Manhart J, Chen H, Hamm G, Hickel R. Buonocore Memorial Lecture. Review of the clinical survival of direct and indirect restorations in posterior teeth of the permanent dentition. Oper Dent. 2004;29:481–508. [PubMed]

4. Macedo G, Raj V, Ritter AV. Longevity of anterior composite restorations. J Esthet Restor Dent. 2006;18:310–1. [PubMed]

5. Zachrisson BU, Mjör IA. Remodeling of teeth by grinding. Am J Orthod. 1975;68:545–53. [PubMed]

6. Heymann HO. Conservative concepts for achieving anterior esthetics. J Calif Dent Assoc. 1997;25:437–43. [PubMed]

7. Leonard RH, Jr, Bentley C, Eagle JC, Garland GE, Knight MC, Phillips C, et al. Nightguard vital bleaching: A long-term study on efficacy, shade retention. Side effects, and patients' perceptions. J Esthet Restor Dent. 2001;13:357–69. [PubMed]

8. Ritter AV, Leonard RH, Jr, St. Georges AJ, Caplan DJ, Haywood VB. Safety and stability of nightguard vital bleaching: 9 to 12 years post-treatment. J Esthet Restor Dent. 2002;14:275–85. [PubMed]

9. Sundfeld RH, Croll TP, Briso AL, de Alexandre RS, Sundfeld Neto D. Considerations about enamel microabrasion after 18 years. Am J Dent. 2007;20:67–72. [PubMed]

10. Donly KJ, Jensen ME. Posterior composite polymerization shrinkage in primary teeth: An *in vitro* comparison of three techniques. Pediatr Dent. 1986;8:209–12. [PubMed]

11. Giachetti L, Scaminaci Russo D, Bambi C, Grandini R. A review of polymerization shrinkage stress: Current techniques for posterior direct resin restorations. J Contemp Dent Pract. 2006;7:79–88. [PubMed]

12. Spreafico RC, Gagliani M. Composite resin restorations on posterior teeth. In: Roulet JF, Degrange M, editors. Adhesion: The Silent Revolution in Dentistry. Chicago: Quintessence Publishing; 2000. pp. 253–76.

13. Lutz F, Krejci I, Barbakow F. Quality and durability of marginal adaptation in bonded composite restorations. Dent Mater. 1991;7:107–13. [PubMed]

14. Tjan AH, Bergh BH, Lidner C. Effect of various incremental techniques on the marginal adaptation of class II composite resin restorations. J Prosthet Dent. 1992;67:62–6. [PubMed]

15. Vanini L. Light and color in anterior composite restorations. Pract Periodontics Aesthet Dent. 1996;8:673–82. [PubMed]

16. Ritter AV. Posterior resin-based composite restorations: Clinical recommendations for optimal success. J Esthet Restor Dent. 2001;13:88–99. [PubMed]

17. Klaff D. Blending incremental and stratified layering techniques to produce an esthetic posterior composite resin restoration with a predictable prognosis. J Esthet Restor Dent. 2001;13:101–13. [PubMed]

18. Coli P, Brännström M. The marginal adaptation of four different bonding agents in Class II composite resin restorations applied in bulk or in two increments. Quintessence Int. 1993;24:583–91. [PubMed]

19. Von Beetzen M, Li J, Nicander I, Sundström F. Microhardness and porosity of class 2 light-cured composite restorations cured with a transparent cone attached to the light-curing wand. Oper Dent. 1993;18:103–9. [PubMed]

20. Ericson D, Dérand T. Reduction of cervical gaps in class II composite resin restorations. J Prosthet Dent. 1991;65:33–7. [PubMed]

21. Dickinson GL, Leinfelder KF, Mazer RB, Russell CM. Effect of surface penetrating sealant on wear rate of posterior composite resins. J Am Dent Assoc. 1990;121:251–5. [PubMed]

22. Opdam NJ, Roeters FJ, Feilzer AJ, Verdonschot EH. Marginal integrity and postoperative sensitivity in Class 2 resin composite restorations *in vivo*. J Dent. 1998;26:555–62. [PubMed]

23. Hassan KA, Khier SE. Split-increment technique: An alternative approach for large cervical composite resin restorations. J Contemp Dent Pract. 2007;8:121–8. [PubMed]

24. Mackenzie L, Shortall AC, Burke FJ. Direct Posterior composites: A practical guide. Dent update. 2009;36:71. [PubMed]

25. Javaheri DS. Placement technique for direct posterior composite restorations. Pract Proced Aesthet Dent. 2001;13:195–200. [PubMed]

26. Summitt JB, Robbins JW, Hilton TJ, Schwart RS, Santos JD. Fundamentals of Operative Dentistry: A Contemporary Approach. Illinois, USA: Quintessence Books; 2006. pp. 289–339.

27. Manauat J, Salat A. An Atlas of Composite Resin Stratification. London: Quintessence Publishing Co Ltd; 2013.

28. Chiche GJ, Pinault A. Esthetics of Anterior Fixed Prosthodontics. London: Quintessence Publishing; ISBN 978-0-86715-258-6.

29. Mackenzie L, Parmar D, Shortall AC, Burke FJ. Direct anterior composites: A practical guide. Dent Update. 2013;40:297. [PubMed]

30. Roopa R, Anupriya B. Effect of four different placement techniques on marginal microleakage in class II restorations: An *in vitro* study. World J Dent. 2011;2:111–6.

31. Khier S, Hassan K. Efficacy of composite restorative techniques in marginal sealing of extended class v cavities. ISRN Dent. 2011;2011:180197. [PMC free article] [PubMed]

32. Szep S, Frank H, Kenzel B, Gerhardt T, Heidemann D. Comparative study of composite resin placement: Centripetal buildup versus incremental technique. Pract Proced Aesthet Dent. 2001;13:243–50. [PubMed]